

Atypical HUS Mistaken for TTP: A Case Report

An Wu, Jiaping Wang, Lixia Sheng* and Guifang Ouyang*

¹Department of Hematology, The First Affiliated Hospital of Ningbo University, Ningbo Clinical Research Center for Hematologic malignancies, Ningbo, China Ningbo, Zhejiang, PR China

***Corresponding Authors:** Lixia Sheng, Department of Hematology, The First Affiliated Hospital of Ningbo University, Ningbo Clinical Research Center for Hematologic malignancies, Ningbo, China Ningbo, Zhejiang, PR China, Tel.: 15968985233, E-mail: slx800408@163.com

Guifang Ouyang, Department of Hematology, The First Affiliated Hospital of Ningbo University, Ningbo Clinical Research Center for Hematologic malignancies, Ningbo, China Ningbo, Zhejiang, PR China, Tel.: 13967810405, E-mail: nbhematology@163.com

Citation: An Wu, Jiaping Wang, Lixia Sheng, Guifang Ouyang et al. (2024) Atypical HUS Mistaken for TTP: A Case Report, SAJ Case Report 11: 103

Abstract

Thrombotic thrombocytopenic purpura (TTP) and atypical hemolytic uremic syndrome (aHUS) are both thrombotic microangiopathies that share several clinical traits including microangiopathic hemolytic anemia, thrombocytopenia, and organic damage. There is inherent opportunity for misdiagnosis. Thus, we report a case of aHUS who was misdiagnosed with TTP. We suggest that the detection of ADAMTS-13 activity and complement gene mutation at an early stage is necessary when the disease is unclear.

Keywords: TMA; aHUS; TTP; complement

Introduction

Thrombotic thrombocytopenic purpura (TTP) and atypical hemolytic uremic syndrome (aHUS) are both thrombotic microangiopathies (TMA) that share many clinical features including microangiopathic hemolytic anemia (MAHA), thrombocytopenia and organ damage [1], thus there is inherent opportunity for misdiagnosis.

TTP and aHUS are two distinct diseases with different pathophysiologies [2]. TTP is characterized by MAHA, thrombocytopenia, neuropsychiatric symptoms, fever, and renal involvement, but acute kidney injury is uncommon [3, 4]. Its pathogenesis mainly involves the deficiency of ADAMTS13 activity, which leads to the failure of timely degradation of the abnormally released super-large molecule von Willebrand factor (VWF), and resulting in ischemia, hypoxia, and organ dysfunction [4]. aHUS, a complement-mediated thrombotic microangiopathy (CM-TMA), is caused by a genetic abnormality in the complement alternative pathway, that primarily affects the kidney [5].

Although the development of molecular diagnostic techniques has improved the accuracy of distinguishing aHUS from TTP [6], to distinguishing different TMA types such as TTP and aHUS still seem hard. Thus, it is important to diagnose aHUS using more accurate detection method.

Herein, we describe a case of a patient who was misdiagnosed with TTP but in the end corrected to aHUS due to timely detection of ADAMTS-13 activity and complement gene mutation.

Case Report

A 54-year-old Chinese male with thrombocytopenia was admitted to our hospital at the end of 2022. He was initially diagnosed of TTP in 2014 and was treated by plasmapheresis and prednisone with no relapse since then. Four days before to admission to the hospital, the patient developed a fever. Physical examination revealed no significant abnormalities. Blood tests showed severe thrombocytopenia (PLT $12 \times 10^9/L$), mild anemia (Hb 99g/L), renal insufficiency (creatinine 291 μ mol/L), VWF 219.1% and ragged-red fiber 1.4% (Figure 1B). Other laboratory results included CRP 19.1mg/L, D-Dimer 9968ng/ml, LDH 1919U/L, direct bilirubin 17 μ mol/L, indirect bilirubin 36.6 μ mol/L. Arterial blood gas indicated acute hypoxic respiratory failure, urinalysis showed microalbuminuria 599mg/L and blood 3+. Computed tomography (CT) of the chest revealed pneumonia and bilateral pleural effusions (Figure 1C). Consanguineous marriage was confirmed in his parents. His brother and sister both had a history of thrombocytopenia, and one went through nephrectomy.

Blood samples of this patient for measuring ADAMTS13 activity and inhibitor levels were collected immediately at admission. With a PLASMIC score of 6, TTP was strongly suspected, and daily plasmapheresis for him was started promptly along with high-dose prednisone impulsion and human immunoglobulin infusion therapy. The patient responded to eight plasmapheresis courses while developed hypotension and hypoxemia during the first week.

After approximately one week later, the result of the patients' ADAMTS13 activity came out as 33.8% (by fluorescence resonance energy transfer; normal: 70–120%) with an antibody titer of 0 (by enzyme-linked immunosorbent assay; normal: undetectable). Additional work up showed a decreased C3 serum level (0.54 g/L; normal range, 0.7–1.4 g/L) and a decreased C4 level (0.08 g/L; normal range, 0.1–0.4 g/L). Thus, we assumed that this patient obtained TMA except TTP and performed a whole exome sequencing for him.

On the 5th week of hospitalization, the patient became refractory with decreasing platelet count since the prednisone being reduced from 100mg to 60mg per day. Treatment was intensified with a course of rituximab (375 mg/m²) but there were no signs

of PLT increasing. On the 6th week, he accepted oral thrombopoietin receptor agonist (TPO-RA) maleate avatrombopag. Two weeks later, his PLT level has been on the rise. And the patient was discharged on prednisone and maleate avatrombopag. The trend of PLT level was showed in Fig. 1A. Soon afterwards the patient discharged, his report of WES came out showing membrane cofactor protein (CD46) and complement factor H (CFH) gene mutation, confirming the diagnosis of aHUS (Figure 1D).

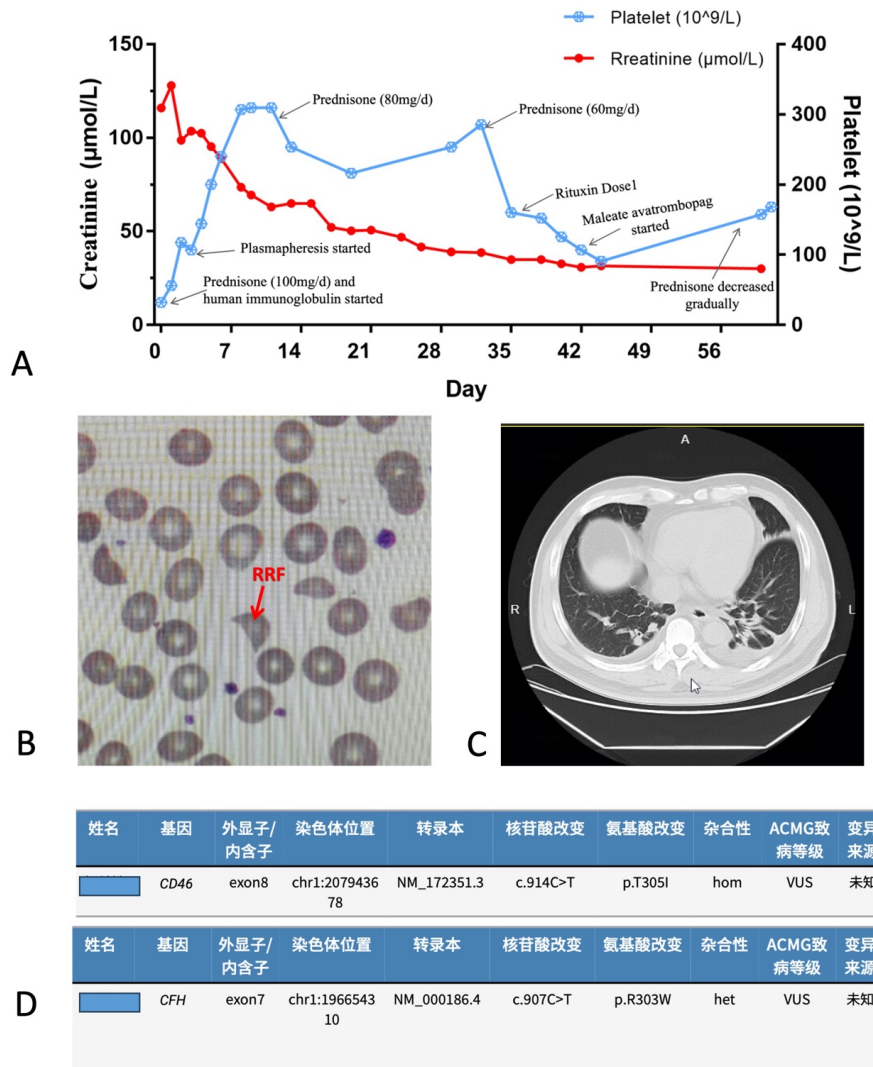


Figure 1: (A) Response in platelets and creatinine indices during treatment. (B) Chest CT scan images. (C) Ragged-red fiber on smear. (D) The CD46 and CFH gene mutation by WES.

Discussion

Several case reports describing aHUS and TTP can be found in the literature. Although 17 cases of pediatrics associated with either TTP or aHUS were reviewed by Adriana Mocanu et al. in 2023 [7], the diagnosis between TTP and aHUS in adult has still not been clearly defined.

Despite having completely different pathogenetic mechanisms, both aHUS and TTP can develop TMA, and both are challenging to diagnose clinically. In our case, the patient was initially diagnosed with TTP because of the high PLASMIC score. However, his ADAMTS13 level was not low enough to diagnose TTP. As we all known, TTP is caused by autoantibodies against ADAMTS-13, a plasma enzyme that cleaves VWF [8]. Thus, the ADAMTS13 level plays an important role in distinguishing

TTP from other TMA types clinically.

On the other side, consanguineous marriages allow the defective genes to remain in the family, so we performed WES and eventually found gene mutations of CD46 and CFH, which was the most frequently affected in aHUS [9]. Agnieszka Furman´czyk-Zawiska et.al showed a series of cases from a single family whose five members were affected by aHUS with next-generation sequencing revealing combined mutations in both CFH and CD46 [10]. A report also demonstrates a high frequency of CD46 mutations in aHUS, closely mimicking relapsing/remitting TTP [6]. Similarly, our patient's brother and sister also had a history of thrombocytopenia. Although there was no WES on them, we have reason to deduce that aHUS can act as a hereditary disease in some families.

The patient's mutation result was delayed. Although standard therapy such as plasmapheresis and prednisone were used, the outcome was dismal. Anti-complement treatment, including eculizumab and ravulizumab, is considered to be successful in treating aHUS [11, 12]. Noteworthy, the PLT of the patient began to improve progressively after using maleate avatrombopag, an oral-small-molecule second-generation TPO-RA, which has not been previously reported in the therapy of TMA. More research is required to verify whether maleate avatrombopag playing the role in the treatment of refractory TMA-associated disorders. The patient might get better recovery by using anti-complement treatment when aHUS being early diagnosed. Therefore, performing genetic screening for complement abnormalities as soon as possible is necessary in differentiating aHUS and TTP.

Conclusion

In conclusion, we reported a case of aHUS who were diagnosed with TTP at first. The timely identification of ADAMTS-13 activity and complement gene mutation is necessary in diagnosing aHUS. This finding provides valuable insights into disease diagnosis of aHUS at a very early stage. There is still much work to be done to untangle the intricate relationships between TTP and aHUS.

Conflicts of Interest Statement

The authors report there are no competing interests to declare

Acknowledgements

We thank the patients and their caregivers. The authors are fully agreed both to be personally accountable for their own contributions and to ensure that questions related to the accuracy or integrity of any part of the work are appropriately investigated, resolved.

Ethical Approval of Studies and Informed Consent

Approval for the retrospective review of these records was obtained from the Ethics Committee of the First Affiliated Hospital of Ningbo University Ningbo and was in accordance with the Declaration of Helsinki.

Consent to participate

The patient provided written informed consent prior to the commencement of the study.

References

1. Zini G, De Cristofaro R (2019) Diagnostic Testing for Differential Diagnosis in Thrombotic Microangiopathies. *Turk J Haematol*, 36: 222-9.
2. Hosler GA, Cusumano Am Fau - Hutchins GM, Hutchins GM (2021) Thrombotic thrombocytopenic purpura and hemolytic uremic syndrome are distinct pathologic entities. A review of 56 autopsy cases. (1543-2165 (Electronic))
3. Page EE, Kremer Hovinga JA, Terrell DR, Vesely SK, George JN (2015) Thrombotic thrombocytopenic purpura: diagnostic criteria, clinical features, and long-term outcomes from 1995 through, 2473-9529.
4. Joly BS, Coppo P, Veyradier A (2017) Thrombotic thrombocytopenic purpura. *Blood*, 129: 2836-46.
5. Raina R, Krishnappa V, Blaha T, et al. (2019) Atypical Hemolytic-Uremic Syndrome: An Update on Pathophysiology, Diagnosis, and Treatment. *Ther Apher Dial*, 23: 4-21.
6. Phillips EH, Westwood JP, Brocklebank V, et al. (2016) The role of ADAMTS-13 activity and complement mutational analysis in differentiating acute thrombotic microangiopathies. *J Thromb Haemost. Jan*, 14: 175-85.
7. Mocanu A, Bogos RA, Lazaruc TI, et al. (2023) Pitfalls of Thrombotic Microangiopathies in Children: Two Case Reports and Literature Review. *Diagnostics (Basel)*, 13.
8. Zheng XL (2024) Mechanism underlying severe deficiency of plasma ADAMTS-13 activity in immune thrombotic thrombocytopenic purpura. *J Thromb Haemost*, 22: 1358-65.
9. Yun JW, Oh J, Lee KO, et al. (2020) Distinct genetic profile with recurrent population-specific missense variants in Korean adult atypical hemolytic uremic syndrome. *Thromb Res*, 194: 45-53.
10. Furmanczyk-Zawiska A, Kubiak-Dydo A, Uzarowska-Gaska E, et al. (2021) Compound Haplotype Variants in CFH and CD46 Genes Determine Clinical Outcome of Atypical Hemolytic Uremic Syndrome (aHUS)-A Series of Cases from a Single Family. *J Pers Med*, 11.
11. Merrill SA, Brittingham ZD, Yuan X, Moliterno AR, Sperati CJ, Brodsky RA (2020) Eculizumab cessation in atypical hemolytic uremic syndrome, 1528-0020.
12. Rondeau E, Scully M, Ariceta G, et al. (2020) The long-acting C5 inhibitor, Ravulizumab, is effective and safe in adult patients with atypical hemolytic uremic syndrome naïve to complement inhibitor treatment.